

SÉRIE “Biologie”

[https://doi.org/10.52058/2695-1592-2024-6\(37\)-265-276](https://doi.org/10.52058/2695-1592-2024-6(37)-265-276)

Olha Panivska

*graduate student of the
Lesya Ukrainka Volyn National University,
Lutsk, Ukraine,
<https://orcid.org/0000-0002-1280-4458>*

Viktor Shevchuk

*Candidate of Veterinary Sciences,
National University of Life and Environmental Sciences of Ukraine,
Kyiv, Ukraine,
<https://orcid.org/0000-0002-1280-4458>*

MYCOBACTERIOSIS OF PRODUCTIVE ANIMALS IN THE CONDITIONS OF DAIRY FARMS

Abstract. The growing incidence of mycobacteriosis in people - infectious diseases caused by non-tuberculous mycobacteria - is an urgent problem in human medicine. Mycobacteriosis of animals in most countries is in the field of close attention of veterinary medicine scientists. In Ukraine, the number of farms where productive animals with para allergic reactions to tuberculin are found is constantly increasing, which complicates the diagnosis of tuberculosis. Therefore, the study of the nature of these allergic reactions becomes one of the most urgent questions of veterinary science. Along with this, in dairy cattle breeding, this problem concerns not only the diagnosis of tuberculosis but also the economic sphere, as it often leads to the forced slaughter of young animals and highly productive cows. On the other hand, identifying several non-tuberculous mycobacteria species in human mycobacteriosis patients, which are involved in sensitizing the body of cows, gives the problem of animal mycobacteriosis prevention a medical and social significance. All of the above was the basis for establishing the reasons for the permanent selection of cows reacting to tuberculin in one of the dairy farms of the Volyn region, which has always been safe from tuberculosis. A comprehensive study using epizootological analysis and clinical, patho-anatomical, histological, bacteriological,

and statistical research methods was carried out from 2018 to 2023. The conducted studies established that an epizootic process caused by infection of animals with non-tuberculosis is functioning among the cattle of a dairy farm mycobacteria. *Mycobacterium scrofulaceum*, *M. fortuitum*, and *Nocardia spp*, which were isolated and identified from the lymph nodes, lymphoid tissue of the submucosal layer of the large intestine of infected animals, cause significant histological and pathoanatomical changes, which indicates the presence of a clinically hidden infectious process, which is accompanied by sensitization of the animal organism. Epizootological analysis of the results of allergic studies using a simultaneous sample, as well as multiple bacteriological studies of biomaterial from animals that reacted positively to PPD-tuberculin and an allergen of atypical mycobacteria, established that allergic reactions to tuberculin had a para allergic nature and reflected the presence of an infectious process in the animal's body.

Keywords: tuberculosis, tuberculin, allergen of atypical mycobacteria, epizootic process, infectious process, allergic reactions, diagnosis.

Formulation of the problem. Animal mycobacteriosis has become an urgent problem in veterinary medicine in many countries (Varela-Castro et al., 2022; Franco et al., 2013). The greatest epizootological and medico-biological significance is the mycobacteriosis of cattle - the primary producers of milk, dairy, and meat products (Aydin et al., 2012; Bolaños et al., 2018). Non-specific (paraallergic) reactions to PPD-tuberculin (Purified Protein Derivative) in tuberculosis-free cows of dairy farms is a phenomenon quite common in many countries of the world, including Ukraine (Gorzheev et al., 2004; Leite et al., 2003; Zavhorodnui et al., 2016). In cases of single detection of para allergic reactions to tuberculin, they are usually not registered, the reasons for their occurrence are not established, and the animals that showed these reactions are culled (Boyko et al., 2020). In cases of such reactions in many animals, a simultaneous test using two allergens - PPD-tuberculin for mammals and AAM (allergen of atypical mycobacteria) is used (Kasych et al., 2004). Specialists of state institutions of veterinary medicine of Ukraine, as a rule, do not record para allergic reactions to tuberculin in cattle, as they believe that non-tuberculous mycobacteria (NTMB) can only cause sensitization of the animal body, but not an infectious process (Zavhorodnii et al., 2018). According to this postulate, sensitization of the animal body is not the result of a hidden infectious process caused by NTMB but a permanent phenomenon that does not cause the appearance of pathological changes in the body.

Most scientists of humane and veterinary medicine believe that mycobacteriosis is an infectious disease caused by NTMB, has its etiopathogenesis, characteristic pathoanatomical and specific histomorphological changes, and is characterized by a primarily asymptomatic, permanent form of sensitization and a chronic course (Boyko et al., 2021; Schmidt et al., 2022; Sandlund et al., 2023; Montero et al., 2023).

For several reasons, it is not easy to objectively assess the intensity of the epizootic situation regarding animal mycobacteriosis in Ukraine. The objective reason for this is a significant reduction in the number of productive animals. In particular, the cattle population decreased from 28 million heads in 1993 to 2.4 million heads in 2023 (Association of Milk Producers, 2023), and such livestock industries as horse breeding, sheep breeding, and rabbit breeding were almost eliminated. The terms of economic exploitation of cows on dairy farms have significantly decreased, which is connected with the change in milk production technology.

Unsatisfactory diagnostic quality by veterinary medicine practitioners and low motivation of specialists of state veterinary medicine institutions in diagnosing new infectious pathology negatively affected the real state of the epizootic situation regarding mycobacteriosis. This, in turn, led to a decrease in the demand for the development of modern methods of diagnosis and means of prevention of infections caused by atypical mycobacteria (ATMB).

The biological properties of ATMB, in particular, the exclusivity of the structure of the cell wall of mycobacteria, which is associated with the presence of fatty and waxy compounds in it, provide high adaptation capabilities of mycobacteria both to changing environmental conditions and resistance to phagocytosis (Weisfeiler, 1975). This enables mycobacteria to survive in changing environmental conditions and is one of the main factors of mycobacterial ubiquity (Nuratinov, 2014; Armstrong et al., 2022).

Studying the features of the infectious process in all cases of detection of reacting animals in each herd of cattle, regardless of its epizootic status, monitoring the features of the epizootic process in each case of detection of para allergic reactions with the help of a simultaneous allergic test can significantly expand our knowledge about infections caused by ATMB. The obtained data can become the basis for creating an information base for an in-depth study of the ecology of these infections' causative agents and mycobacteria's epizootology. Moreover, this, in turn, will be an objective basis for developing concepts for controlling and managing infectious and epizootic processes in animal mycobacteriosis.

Analysis of recent research and publications. Data from the scientific literature indicate that human and animal mycobacteriosis caused by NTMB is an essential problem of humane and veterinary medicine in many countries of the world (Alffenaar, J.W., 2021; Varela-Castro et al., 2022). Mycobacteriosis of cattle has the most significant medical and biological importance because it is the leading producer of dairy and meat products (Bolaños et al., 2018). In cows, non-specific reactions to PPD-tuberculin (Purified Protein Derivative) are common in Ukraine (Zavhorodnui et al., 2016). However, veterinary medicine specialists believe that non-tuberculous mycobacteria (NTMB) can only cause sensitization of the animal body but not the infectious process (Zavhorodnii et al., 2018). However, most



scientists believe mycobacteriosis is an infectious disease caused by atypical mycobacteria (Boyko et al., 2021; Schmidt et al., 2022; Sandlund et al., 2023). Therefore, studying etiopathogenesis and features of the infectious process in animals reacting to tuberculin or allergen atypical mycobacteria is an essential and urgent scientific research problem.

The goal of the article. Study the nature of para allergic reactions to tuberculin in cows of a tuberculosis-free farm.

Research material and methods. The study was conducted in one of the dairy farms in the Volyn region during 2018–2023. It used epizootological analysis, clinical, allergic, patho-anatomical, histological, bacteriological, and statistical research methods.

The epizootic situation regarding tuberculosis was analyzed based on the results of allergic studies, which were carried out according to the calendar of anti-epizootic measures by specialists of the district administration of veterinary medicine with our participation during the specified period.

During the clinical examination, attention was paid to the general condition of the animals, their fatness, and the condition of the lymph nodes - pharyngeal, submandibular, prescapular, inframammary, and knee fold.

Allergic studies of animals for tuberculosis were carried out using a simultaneous test. Allergens were injected intradermally with a needle-free injector into the middle third of the neck at a dose of 0.1 cm³, PPD-tuberculin for mammals on the left, allergen from atypical mycobacteria (AAM) on the right.

Animals that reacted positively to PPD-tuberculin and AAM were selected for diagnostic slaughter. Animals were slaughtered on the 5th–seventh day after the allergy test.

From animals killed for diagnostic purposes, lymph nodes (pharyngeal, submandibular, prescapular, bronchial, mediastinal, portal, mesenteric, supra mammary, knee fold), as well as pieces of parenchymal organs (lungs, liver, spleen), and altered areas of the large intestine were selected.

Smears were prepared from lymph nodes and internal organs and stained by the Zill-Nielsen method (for conventional light microscopy) and auramine O (for luminescent microscopy).

The material for histological examination was fixed in a 10% neutral formalin solution. After thorough washing, the material was embedded in paraffin. Paraffin blocks were cut serially, and the thickness of the sections was five µm. Sections were stained with hematoxylin and eosin (Manchenko et al., 1994).

Microphotography was performed on a ZEISS Primo Star 3 microscope, with the help of an Axiocam 208 color digital camera and Zen ZEISS software.

A bacteriological examination of the biomaterial was carried out by inoculation on the Levenstein-Jensen medium. The material was pre-sowed treatment according to Alikaeva's method (Feshchenko et al., 2019).

Results and their discussion. Control of the epizootic process for bovine tuberculosis is carried out comprehensively. However, priority is given to timely and effective diagnosis, mainly the allergic method (Busol et al., 2014).

The study of the infectious process of mycobacteriosis in the cows of the dairy farm under investigation by us was carried out comprehensively after each planned allergic examination of the dairy herd using clinical, patho-anatomical, histomorphological, and microbiological methods. The analysis of the obtained data made it possible to reveal the peculiarities of the manifestation of the infectious process and to identify the main driving forces of the epizootic process for mycobacteriosis of animals in the herd. During the period 2018–2023, 12 allergy studies of the dairy herd of the farm were conducted (results are provided in Table 1).

Table 1

Results of an allergic study of cows for tuberculosis by simultaneous sampling for 2018–2023

№	Date of study	Allergically tested, heads	Identified responders to:					
			PPD-tuberculin		Allergen from atypical mycobacteria (AAM)		PPD-tuberculin and allergen from atypical mycobacteria (AAM)	
			heads	%	heads	%	heads	%
1	29.05–1.06.2018	330	9	2,7	38	11,5	132	40,0
2	28.11–1.12.2018	419	12	2,9	56	13,4	95	22,7
3	11–14.06.2019	341	10	2,9	34	10,0	102	29,9
4	16–19.10.2019	429	9	2,1	21	4,9	106	24,7
5	18–21.03.2020	356	3	0,8	55	15,4	103	28,9
6	20–23.10.2020	446	3	0,7	60	13,5	108	24,2
7	20–23.04.2021	369	7	1,9	66	17,9	99	26,8
8	26–29.10.2021	395	2	0,5	17	4,3	36	9,1
9	18–21.04.2022	446	5	1,1	54	12,1	25	5,6
10	19–22.10.2022	432	0	0,0	35	8,1	20	4,6
11	17–20.05.2023	438	3	0,7	69	15,8	11	2,5
12	24–10.10.2023	428	5	1,2	24	5,6	18	4,2
Together		4829	68	1,4	529	11,0	855	17,7

As can be seen from Table 1, as a result of the allergic studies conducted during the entire period, 1,452 reacting animals were identified, of which only 68 animals reacted to PPD-tuberculin for mammals, only 529 animals to AAM and 855 animals to both allergens. The average percentage of reacting animals from the total number investigated was only PPD-tuberculin for mammals – 1.4%; only AAM -

11% and for both allergens at the same time - 17.7%. That is, the ratio of the number of animals reacting to tuberculin to the number of animals that gave positive reactions to AAM and AAM and tuberculin is 1: 20.5. Even a cursory statistical analysis indicates that allergic reactions to AAM are decisive, and reactions to PPD-tuberculin appear as side effects, random. The results indicated that the animal body is under constant antigenic pressure from NTMB, and the allergic reactions of animals to the introduction of tuberculin are not related to the tuberculosis process. On the other hand, it can be stated that the antigenic determinants of certain types of NTMB have a high affinity to the antigens of *Mycobacterium tuberculosis*, and the results of allergic studies conducted by us over a long period confirm this.

So, from an immunological point of view, the situation is understandable and does not cause concern. Even on the basis of epizootological analysis, it is clear that in the researched herd of animals, there is a population or populations of NTMB circulating, which causes sensitization of the cow's body and, it is possible, an infectious process, but sensitization is only a manifestation of the latter.

From the point of view of epizootological control and supervision, for planned allergic studies on tuberculosis, detecting animals reacting to PPD-tuberculin involves long and painstaking work to establish the nature of these reactions. Often, in such a situation, specialists of the state veterinary medicine service ignore the requirements of the "Instructions for the Prevention and Control of Animal Tuberculosis" (2009) and send reacting animals to slaughter without conducting additional studies (Boyko et al., 2020). With each subsequent allergy study of the herd, the number of animals that react positively to tuberculin does not decrease but increases. This approach inevitably leads to the unjustified slaughter of productive animals and, in modern conditions of small dairy farms, often to the complete liquidation of the dairy herd. At the same time, the situation remains uncontrolled in terms of epizootic well-being and, most importantly, unstudied, and therefore unpredictable in terms of further use of the premises and territory of the farm.

From 2018 to 2023, 12 comprehensive studies of the dairy herd were conducted with the organization of diagnostic slaughter, during which material from 74 animals reacting to both allergens was examined.

The results of the clinical examination of animals that gave positive reactions to one or both allergens did not reveal in any of the animal's signs that could indicate the infectious process of tuberculosis in their body (weight loss or cachexia, decreased milk production, increased superficial lymph nodes, cough or other signs of lung damage).

Studying the epizootological features of mycobacteriosis of cows on a specific farm, it was established that the number of cows reacting to both allergens is significantly (2–3 times) higher during an allergy study after winter-stable keeping of animals compared to those during summer-walking (table 1). Thus, keeping animals in the summer for several months on walking grounds is accompanied by

the improvement of the animal's body from the so-called "barn" microflora, including and from mycobacteria of various species. It can be assumed that a significant reduction of the antigenic load on the body of NTMB cows would negate the infectious process in the body of infected animals and, thus, sensitization of the body of cows to allergens of atypical mycobacteria.

Of the 74 animals slaughtered for diagnostic purposes, in which positive reactions to allergens were noted, patho-anatomical changes characteristic of tuberculosis were not detected. However, in all the cows slaughtered for diagnostic purposes, several other pathological changes in the lymphatic nodes were noted, in particular:

- granulomatous foci,
- atrophy of lymphoids and growth of epithelioid tissues,
- hyperplasia of various intensities and character,
- spotty hemorrhages in the cortical zone.

In addition, changes in the color of the parenchyma (redness or dark gray color), salinity, and replacement of the parenchyma of the node by connective tissue, indicating the presence of atrophic processes, were detected in the lymph nodes. Atrophy of the lymphoid tissue is evidenced by the growth of connective tissue, which pushes the lymphoid tissue to the periphery of the cortical zone, the remnants of which are visible as a narrow strip on the periphery of the node (Fig. 1).

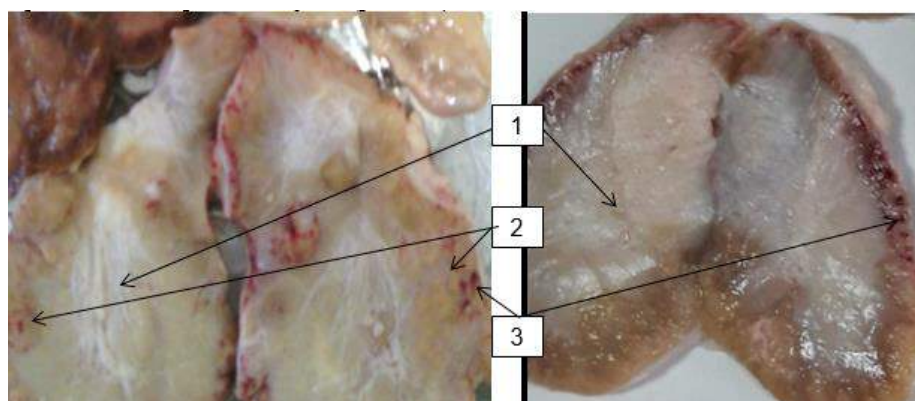


Fig. 1. Pathological-anatomical changes in supra mammary lymph nodes. Note: 1 – degeneration with complete atrophy of the brain layer parenchyma; 2 – remnants of parenchyma in the cortical layer; 3 – hemorrhages in the cortical area.

Hyperplasia of lymph nodes was manifested by the growth of lymphoid tissue and infiltration by lymphocytes, which is evidence of the presence of hidden inflammatory processes in the nodes' tissues. Hyperplasia indicates a cellular reaction of lymphoid tissue to foreign antigens - bacteria, fungi, etc. In the described case, these are acid-resistant types of NTMB, which were isolated from the tissue of lymph nodes during bacteriological research. They sensitized the immune system not only to its antigens, which manifested itself in the form of allergic reactions to



AAM, but also to antigens of other types of mycobacteria, in particular tuberculosis, which was the cause of para allergic reactions to tuberculin.

A detailed epizootological analysis of para allergic reactions to both antigens indicates their permanent nature - in a number of cows, the reactions repeatedly disappeared and reappeared during the observation period. Obviously, with age, as a result of a decrease in immunoreactivity, which develops against the background of atrophy of the lymphoid tissue of the lymph nodes and, it is possible, other causes of an immunoallergic nature, there is a decrease in sensitization, which is accompanied by the loss of these reactions. Thus, the histological changes found in the histosections from the lymph nodes indicate an active infectious process, which could be caused by the products of bacterial life (Fig. 2). At the site of the death of lymphocytes, cellular detritus is formed, a pronounced primary nodule is formed, which is surrounded by a significant layer of lymphocytes.

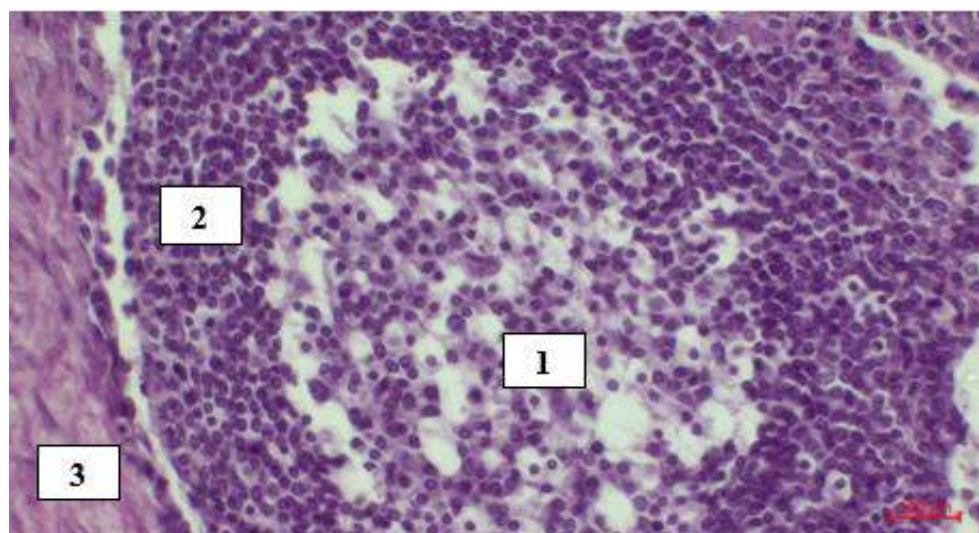


Fig. 2. Formation of nodules in NTBM-infected lymph nodes at a later stage of the infectious process (staining with hematoxylin and eosin. Magnification $\times 400$). Note: 1 – necrosis of lymphocytes in the center of the nodule, fragmentation of nuclei and condensation of chromatin, shedding of entire areas of dead cells; 2 – zone of lymphocytes around the detritus; 3 – a capsule of epithelioid cells.

Similar morphological changes were found on his sections from enlarged lymph nodes, where the formation of primary nodules with cellular detritus in the center, a peripheral accumulation of lymphocytes, and a visible capsule of epithelioid elements were noted.

In previous works, we established that the incubation period for mycobacteriosis caused by NTMB in animals is significantly more extended (in our case, more than 18–26 months) than for tuberculosis infection caused by *M. bovis*. This fact can explain the reasons for animals' delayed response to the introduction of allergens (Boyko et al., 2020). Scientists who studied the pathogenesis of mycobacteria in humans share this opinion (Shevchenko et al., 2019; Zimina et al., 2017).

Bacteriological examination of biological material (lymph nodes and affected areas of the large intestine) from animals reacting to both allergens isolated and identified acid-resistant NTBM, particularly *M. fortuitum*, *M. scrofulaceum*, *Nocardia* spp.). The results of the bacteriological examination of biomaterials from animals slaughtered for diagnostic purposes provide grounds for asserting that allergic reactions to PPD-tuberculin and AAM result from a hidden infectious process that leads to sensitization of the body by these microorganisms. It is evident that the sensitization of the body by NTBM antigens begins already at the stage of formation of primary nodules in the reactive centers of the lymph nodes and is permanently supported by each subsequent entry into the body of a fresh portion of NTBM from the external abiotic environment.

The main routes of entry of NTMB into the animal body are considered the alimentary and aerogenous routes because microorganisms colonize mainly the digestive and respiratory organs and stay the longest in the regional lymph nodes of these organs. This leads to deep pathomorphological changes at the cellular and tissue levels, which were revealed thanks to detailed patho-anatomical and histological studies.

The localization of pathological changes caused by NTMB in the proximal part of the large intestine indicates the tropism of mycobacteria to tissues and organs rich in lymphoid elements (Urbanovych et al., 2008). Here, mycobacteria can be in the enterobiotic phase of existence, colonizing not only places of concentration of lymphoid elements, which are Peyer's patches but also other structures of the submucosal layer of the wall of the large intestine (Boyko et al., 2020). The enterobiotic phase of the existence of NTMB in the body is an endogenous source of constant infection of body tissues and organs, and therefore maintenance of the infectious process of mycobacteriosis in the body and its sensitization.

Significant patho-anatomical and histomorphological changes in the enlarged lymph nodes indicate that NTMB is eliminated through the mammary gland, and therefore, milk should be considered an important factor in the mechanism of transmission of the infectious agent.

Given the significant distribution of NTBM of mycobacteria in nature (Turko et al., 2010; Falkinham et al., 2013), their essential role in human infectious pathology (Barbova et al., 2019; Lipner et al., 2017; Dahl et al., 2023) and animals (Cvetnić et al., 2018; Hejlíček et al., 1994; Radulski et al., 2022), each case of establishing the functioning of the epizootic process of mycobacteria in herds of productive animals, and especially cows, should be considered through the prism of risks for health people through food products obtained from animals suffering from mycobacteriosis, and be subject to epizootological control and supervision by specialists of the state veterinary medicine service.

Conclusions. A comprehensive study of cattle for tuberculosis in the tuberculosis-free economy of the Volyn region during 2018–2023 using epizootological, allergic,



clinical, patho-anatomical, histological, and bacteriological methods established that allergic reactions to tuberculin were para-allergic, arising as a result of an infectious process in the body of cows caused by non-tuberculous mycobacteria.

The incubation period for infection of the body of cattle with NTMB is much more extended than for infection with the causative agent of tuberculosis. It is 18–26 months, and the manifestation of para allergic reactions is permanent, primarily related to the intensity of infection of animals with NTMB.

Non-tuberculous mycobacteria colonize mainly the digestive and respiratory organs, which indicates their alimentary and aerogenic ways of entering the bodies of animals. They linger for the longest time in the regional lymph nodes of these organs, where they cause profound and often irreversible pathomorphological changes at the cellular and tissue levels, which were discovered thanks to detailed patho-anatomical and histological studies. Significant patho-anatomical and histomorphological changes in the enlarged lymph nodes indicate the elimination of NTMB through the mammary gland, and therefore, milk should be considered as a factor in the mechanism of transmission of the infectious agent.

The detected pathomorphological changes in the reacting animals make it possible to ascertain the presence of an intensive infectious process caused by NTMB in their bodies and the functioning of the epizootic process of mycobacteriosis in the dairy herd of cows. Therefore, the reacting animals should be considered an active source of NTMB.

A detailed study of the species composition of NTMBs that caused the infectious process in infected animals, the functioning of the epizootic process on the farm's territory, the ecology of identified and not yet identified NTMBs on the farm's territory, and the establishment of their potential pathogenetic properties will have not only epizootological, economic, and medical but also epidemiological value.

Considering the significant role of NTMB in human infectious pathology, each case of establishing the functioning of the epizootic process of mycobacteria in herds of productive animals should be considered as a source of potential risks for human health in the food chain. Therefore, the following studies will focus on the in-depth study of other aspects of the infectious process of mycobacteria, the ecology of NTMB on the territory of a dairy farm, and ways to minimize the risks of human infection with NTMB through meat and dairy food products.

References:

1. Varela-Castro, L., Barral, M., Arnal, M.C., Fernández de Luco, D., Gortázar, C., Garrido, J. M., & Sevilla, I.A. (2022). Beyond tuberculosis: Diversity and implications of non-tuberculous mycobacteria at the wildlife-livestock interface. *Transboundary and emerging diseases*, 69(5), e2978-e2993.

2. Franco, M.M., Paes, A.C., Ribeiro, M.G., Pantoja, J.C., Santos, A.C., Miyata, M., Leite, J., Motta, R., & Listoni, F. (2013). Occurrence of mycobacteria in bovine milk samples from both individual and collective bulk tanks at farms and informal markets in the southeast region of Sao Paulo, Brazil. *BMC Veterinary Research*, 9, 85.

3. Aydin, F., Ulger, M., Emekdaş, G., Aslan, G., & Günal, S. (2012). Isolation and identification of mycobacterium bovis and non-tuberculous mycobacteria in raw milk samples in Mersin province. *Bulletin of microbiology*, 46, 283-289.
4. Bolaños, C.A., Paula, C.L., Guerra, S.T., Franco, M.M., & Ribeiro, M.G. (2017). Diagnosis of mycobacteria in bovine milk: an overview. *Revista do Instituto de Medicina Tropical de São Paulo*, 59, e40.
5. Gorzheev, V.M., Kassich, Yu.Ya., Zavorodniy, A.I., Pavlenko, M.S., & Kassich, V.Yu. (2004). Dosyahnennya v borot'bi z tuberkul'ozom velykoyi rohatoyi khudoby v hospodarstvakh Ukrainy [Achievements in the fight against tuberculosis of cattle in the farms of Ukraine.] *Veterinary medicine, Interdepartmental Thematic Scientific Collection*, 84, 268-271. [in Ukrainian].
6. Leite, C.Q., Anno, I.S., Leite, S.R., Roxo, E., Morlock, G.P., & Cooksey, R.C. (2003). Isolation and identification of mycobacteria from livestock specimens and milk obtained in Brazil. *Memórias do Instituto Oswaldo Cruz*, 98, 319-323.
7. Zavorodniy, A.I., Bilushko, V.V., Zagrebnyi, V.O., & Balym, Yu.P. (2016). Vyvchennya sensybilizuyuchykh vlastyvostey atypovykh mikobakteriy, vydilyenykh z biomaterialu velykoyi rohatoyi khudoby ta ob'yektiv navkolyshn'oho seredovyshcha [Study of sensitizing properties of atypical mycobacteria isolated from biomaterial from cattle and from environmental objects.] *Veterinary medicine : Interdepartmental thematic scientific collection*, 102, 84-87. [in Ukrainian].
8. Boyko, P.K., Boyko, O.P., Nychyk, S.A., Sytnik, V.A., & Mazur, V.M. (2020). Formuvannya zarazhenosti velykoyi rohatoyi khudoby atypovymy mikobakteriyamy v okremomu stadi [Formation of infection of cattle with atypical mycobacteria in a separate herd.] *Veterinary Biotechnology Bulletin*, 36, 9–21. [in Ukrainian].
9. Kassych, Yu.Ya., Zavorodnyi, A.I. & Kassych, V.Yu. (2004). Odnochasna alerhichna proba dlva diahnostyky tuberkul'ozu (Korovy, vaki utrymuyut'sya v selyans'kykh hospodarstvakh riznykh rehioniv Ukrainy) [Simultaneous allergic test for the diagnosis of tuberculosis (Cows kept in peasant farms of various regions of Ukraine)]. *Veterinaria*, 8, 16–18. [in Ukrainian].
10. Zavorodnii, A.I., Bilushko, V.V., & Kalashnyk, M.V. (2018). Psevdoalerhichni reaktsiyi na tuberkulin u velykoyi rohatoyi khudoby [Pseudoallergic reactions to tuberculin in cattle]. *Veterinary biotechnology*, 32 (2). 176-184. [in Ukrainian].
11. Boyko, P.K., Nychyk, S.A., Boyko, O.P., Tytyuk, O.V., & Shevchuk, V.M. (2021). Mikobakterioz velykoyi rohatoyi khudoby – spontanne zarazhennya v okremomu hospodarstvi chy kompleksna epidemiologichna problema? [Mycobacteriosis of cattle – a spontaneous infection in a separate farm or a complex epidemiological problem?]. *Veterinary Biotechnology Bulletin*, 39, 18-28. [in Ukrainian].
12. Schmidt, V., Köhler, H., Heenemann, K., & Möbius, P. (2022). Mycobacteriosis in Various Pet and Wild Birds from Germany: Pathological Findings, Coinfections, and Characterization of Causative Mycobacteria. *Microbiology spectrum*, 10(4), e0045222.
13. Sandlund, N., Skår, C., & Karlsbakk, E. (2023). First identification of mycobacteriosis in Atlantic mackerel (*Scomber scombrus*). *Journal of Fish Diseases*, 46, 527-533.
14. Montero, E., Rojo-Solis, C., Castro, N., Fernández, M., Perez, V., Corpa, J., et al. (2022). Clinical and Pathological Findings Associated with Mycobacteriosis in Captive Syngnathids. *Animals*, 12, 3259.
15. Busol, V., Boyko, P., Bednarski, M., Shevchuk, V., & Mazur, V. (2023). Patomorfologichni zminy v orhanakh peryferychnoyi imunnoyi systemy pry mikobakteriozi velykoyi rohatoyi khudoby [Pathomorphological changes in the organs of the peripheral immune system in mycobacteriosis of cattle]. *Ukrainian Journal of Veterinary Sciences*, 14(2), 9-27. [in Ukrainian].
16. Asotsiatsiya vyrobnykiv moloka [Association of milk producers].(n.d.). Retrieved from www.avm-ua.org. [in Ukrainian].
17. Weisfeiler, Yu.K. (1975). Biology and variability of Mycobacterium tuberculosis and atypical mycobacteria: Experimental and theoretical studies: trans. from Hungarian, Budapest: Publishing House of the Academy of Sciences of Hungary, 334 p.
18. Nuratinov, R.A. (2014). Ecological conditions of existence of mycobacteria populations. *The South of Russia: ecology, development*, 2, 18–30.

19. Armstrong, D.T., Eisemann, E., & Parrish, N.A. (2023). Brief Update on Mycobacterial Taxonomy, 2020 to 2022. *Journal of Clinical Microbiology*, 61(4), e0033122.
20. Manchenko, V. M., Trotsenko, Z. R. & Pavlenko, M. S., (1994). *Metodychni vказivky z diahnostryky tuberkul'ozu tvaryn i ptytsi: navch. posibnyk [Guidelines for the diagnosis of tuberculosis in animals and poultry: training. manual].* Kyiv: «Urojai». 39 p. [in Ukrainian].
21. Feshchenko, Yu. I., Zhurylo, O. A. & Barbova, A. I. (2019). *Laboratorna diahnostryka tuberkul'oznoyi infektsiyi: navch. Posibnyk [Laboratory diagnosis of tuberculosis infection: training. manual].* Kyiv: VSW «Medicine». 304 p. [in Ukrainian].
22. Busol, V.O., Shevchuk, V.M., Mazur, V.M. & Kovalenko, L.V. (2014.). *Evolutsiya intensyvnosti epizootychnoho protsesu tuberkul'ozu velykoyi rohatoyi khudoby v krayinakh svitu [The evolution of intensity of the epizootic process of bovine tuberculosis in the countries of the world].* *Sciences release vet. of medicine* 14(114). 74–77. [in Ukrainian].
23. Shevchenko, O. Š., Todoriko, L. D., Potejko, P. I., & Pogorelova, O. S. (2019). *Pytannya diahnostryky ta likuvannya netuberkul'oznykh mikobakterioziv [Issues of diagnosis and treatment of non-tuberculous mycobacteriosis].* *East European journal of internal and family medicine*, 1, 36-53. [in Ukrainian].
24. Zimina V. N., Degtyaryova, S. Yu., Beloborodova, E. N., Kulabukhova, E. I., Rusakova, L. I., Fesenko, O. V. (2017). *Suchasny stan mikobakteriozu [A current state of mycobacteriosis].* *Clinical microbiology and antimicrobial chemotherapy*, 19(4), 276–282. [in Ukrainian].
25. Boyko, P. K., Nychyk, S. A., Boyko, O. P., Mandigra, Y. M., & Shevchuk, V. M. (2020). *Osoblyvosti infektsiyno-epizootychnoho protsesu mikobakterioziv velykoyi rohatoyi khudoby, sprychynenykh atypovymy kyslotostiykymy mikobakteriyamy [Features of the infectious and epizootic process of mycobacteriosis of cattle caused by atypical acid-resistant mycobacteria].* *Veterinary biotechnology*, 37, 7-19. [in Ukrainian].
26. Urbanovych, P. P., Pototskyi, M. K., Gevkan, I. I., Zon, G. A., Borysevich, B. V., Papchenko, I.V., et al. (2008). *Patolohichna anatomiya tvaryn [Pathological anatomy of animals].* Kyiv, Vetinform. 896 p. [in Ukrainian].
27. Turko, I.B., Kulyaba, O.V., Semanyuk, V.I., & Pelenho, R.A. (2010). *Tsyrukulyatsiya atypovykh mikobakteriy u zovnishn'omu seredovyshchi ta orhanizmi tvaryn yak prychyna pozytyvnykh alerhichnykh reaktsiy [Circulation of atypical mycobacteria in the external environment and the body of animals as a cause of positive allergic reactions].* *Scientific Bulletin of the LNUVMBT named after S.Z. Gzhitskyi*, 12. 3(45), Part 1. 274-280. [in Ukrainian].
28. Falkinham, J.O. (2013). *Ecology of nontuberculous mycobacteria – where do human infections come from?* *Seminars in Respiratory and Critical Care Medicine* , 34(1), 95–102.
29. Lipner, E.M., Knox, D., French, J., Rudman, J., Strong, M., & Crooks, J.L. (2017). *A Geospatial Epidemiologic Analysis of Nontuberculous Mycobacterial Infection: An Ecological Study in Colorado.* *Annals of the American Thoracic Society*, 14(10), 1523–1532.
30. Dahl, V.N., Floe, A., & Wejse, Ch. (2023). *Nontuberculous mycobacterial infections in a Danish region between 2011 and 2021: evaluation of trends in diagnostic codes.* *Infectious diseases (London, England)*, 55(6), 439–443.
31. Barbova, O.A., Trofimova, A.I., & Myronchenko, P.S. (2019). *Vyvchennya vydovoho riznomanittya netuberkul'oznykh mikobakteriy u riznykh rehionakh Ukrayiny za dopomohoyu metodiv fenohentypichnoyi identyfikatsiyi [Study of species diversity of nontuberculous mycobacteria in different regions of Ukraine using phenogenotypic identification methods].* *Ukrainian pulmonology journal*, 1, 27–30. [in Ukrainian].
32. Cvetnić, Ž., Tuk, M.Z., Duvnjak, S., Reil, I., Mikulić, M., Pavlinec, Ž., et al. (2018). *Tuberculous and Nontuberculous Mycobacteria in Human and Animal Infection.* *Veterinary Journal of Republic of Srpska (Banja Luka)*, 18(2), 342–369.
33. Hejlíček, K., & Treml, F. (1994). *Epizootiology and pathogenesis of avian mycobacteriosis in domestic pigeons (Columba livia f. domestica).* *Veterinary Medicine (Praha)*, 39(10), 615–624.
34. Radulski, Ł., Kalicki, M., Krajewska-Wędzina, M., Lipiec, M., & Szulowski, K. (2022). *Pulmonary mycobacteriosis of sitatunga antelope caused by M. avium ssp. hominissuis.* *Annals of Agricultural and Environmental Medicine*, 29(2), 220-223.